

# The Effect of Labral Repair and Resection on Hip Cartilage Compression

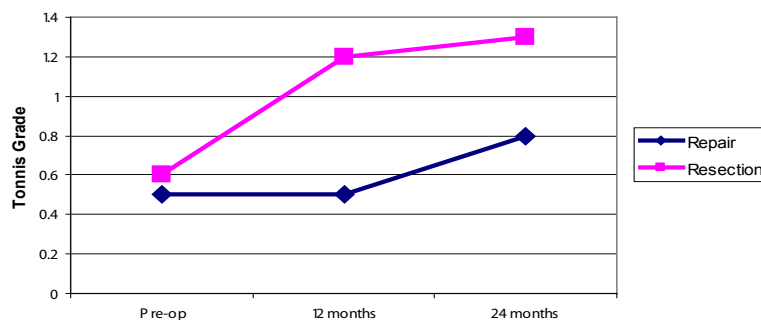
*A summary of a paper published in the Journal of Biomechanics: "Effect of acetabular labral tears, repair and resection on hip cartilage strain: A 7T MR study" 43(5):858-863. 2010.*

## Abstract

Although pain symptoms in acetabular labral tear patients resolve promptly following labral repair or resection procedures,<sup>(1-3)</sup> the long-term clinical outcomes of labral resection have been shown to be linked to the progression of osteoarthritis.<sup>(4,5)</sup> The purpose of this paper is to summarize the findings of a recent study that evaluated cartilage compression when the labrum was repaired versus resected. A total of six human cadaver hips were evaluated. Each hip with an intact labrum was scanned using a 7.0T MRI system while subjected to a load simulating single leg stance. The same hip was then scanned again after an arthroscopically simulated labral tear, after a labral repair, and again after a labral resection. From each high resolution MRI scan, cartilage thickness in the anterosuperior region was measured in three dimensions using advanced imaging techniques. Labral resection resulted in significantly higher mean ( $p=0.020$ ) and maximum ( $p=0.023$ ) cartilage compression compared to labral repair. This increase in cartilage compression due to labral resection may play a role toward the progression of osteoarthritis. The findings support repairing rather than resecting the labrum, whenever possible.

## Introduction

Many clinicians report successful case studies where pain was resolved in patients promptly following labral resection<sup>(1-3)</sup> and labral repair.<sup>(3,6)</sup> However, in contrast to labral repair, the long-term outcomes of labral resection indicate a progression toward osteoarthritis<sup>(4,5)</sup> (Figure 1).



**Figure 1:** Mean pre and postoperative scores for degenerative changes in 52 patients having either a labral repair or resection procedure.

**Note:** A higher Tonnis Grade indicates increased signs of osteoarthritis. Data extracted from Espinosa et al, JBJS 2006.

It is widely accepted that a change in joint mechanics plays a role in the etiology of osteoarthritis<sup>(7)</sup>. It is known that the labrum contributes to a 21% increase in surface area in contact with the femoral head, thereby distributing forces more evenly across the joint, sparing cartilage from excessive compression<sup>(8)</sup>. Further knowledge of the mechanical role of the labrum would be beneficial toward improving current treatment strategies. The objective of this paper was to summarize the findings from a recent Smith & Nephew sponsored biomechanical study that evaluated hip cartilage compression when the labrum was intact, torn, repaired, and resected<sup>(9)</sup>.

## Methods

Six young human cadaver hips (aged 20–48 years) were dissected of all superficial soft tissues, leaving the capsule intact. An arthroscopic examination was performed on each specimen to assure no major pre-existing labral pathology was present. With the labrum intact, and the joint unloaded, the specimen was mounted in an MRI compatible pneumatic loading device and placed in an orientation simulating single leg stance. Thereafter, the specimen was scanned in a 7.0 Tesla MRI system (Bruker Biospin, Germany), obtaining a high resolution image (0.1 mm in-plane resolution, 0.3 mm slice thickness). Three dimensional contours of the cartilage were obtained from the MR image (Analyze 8.0, Mayo Clinic, MN, USA). These contours were then exported as 3D data points and cartilage thickness in the anterosuperior region of the hip was measured radially in three dimensions using a custom program (Matlab 7.0, Mathworks, MA, USA).

The same hip was scanned again while subjected to a compressive force (simulating single leg stance)<sup>(10)</sup>, and under the following conditions:

1. Labrum intact
2. An arthroscopically simulated 3 cm long labral tear in the anterosuperior region, detaching the labrum from the acetabular rim
3. An arthroscopic labral repair using three 2.3 mm BIORAPTOR<sup>®</sup> Suture Anchors, inserted using a straight ARTHRO-PIERCE<sup>®</sup> device for suture passage
4. An arthroscopic labral resection, removing the 3-cm length of torn labrum using sharp knife resection.

Cartilage thickness distribution was measured after each condition, for each of 6 hips. Mean and maximum cartilage compression as a percentage of the original cartilage thickness were compared using a 1-tailed paired t-test.

## Results and Discussion

### Intact versus Torn Labrum

There was no significant difference in the mean or maximum cartilage compression when the labrum was intact ( $33 \pm 8\%$  and  $45 \pm 9\%$  respectively) versus torn ( $32 \pm 7\%$  and  $46 \pm 7\%$  respectively).

The lack of change to the cartilage compression when the labrum was intact compared to the presence of a labral tear detachment from the bone may be due to the type of simulated tear. The torn labrum was still able to maintain the amount of surface area in contact with the femoral head because both ends of the labrum were affixed to the healthy adjacent labrum.

## Torn versus Repaired Labrum

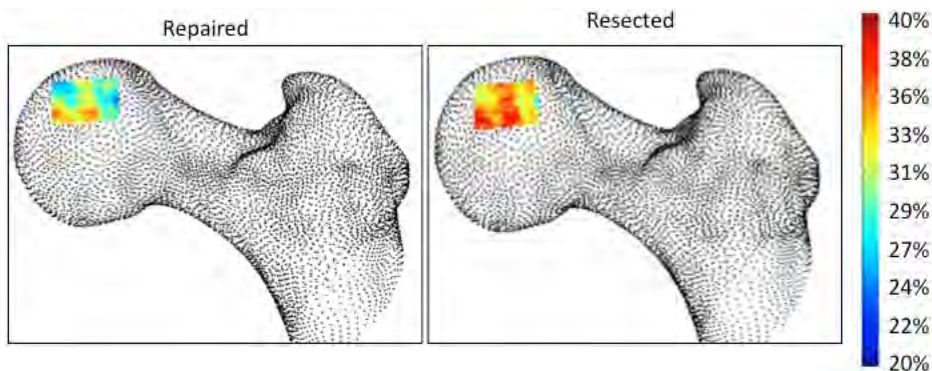
Mean cartilage compression was significantly decreased when the labrum was repaired ( $30 \pm 8\%$ ) versus torn ( $32 \pm 7\%$ ,  $p=0.014$ ). There was no significant difference in the maximum cartilage compression when the labrum was repaired ( $44\% \pm 10\%$ ) versus torn ( $46 \pm 7\%$ ).

The significantly decreased mean cartilage compression following labral repair compared to the torn labrum may have resulted due to the circumferentially stiffer repaired labrum which may distribute forces to the cartilage more effectively.

## Repaired versus Resected Labrum

Mean cartilage compression was significantly increased when the labrum was resected ( $34 \pm 6\%$ ) versus repaired ( $30 \pm 8\%$ ,  $p=0.020$ ). Maximum cartilage compression was also significantly increased when the labrum was resected ( $50 \pm 6\%$ ) versus repaired ( $44 \pm 10\%$ ,  $p=0.023$ ). The population averaged cartilage compression distribution showed an overall increase in compression magnitude throughout the region of interest (**Figure 2**).

An increase in cartilage compression may play a significant role toward the progression of osteoarthritis. The increase in cartilage compression when the labrum was resected is likely due to the decrease in surface area of the labrum in contact with the femoral head.



**Figure 2:** Hip cartilage compression as a percentage of the original cartilage thickness when the labrum was (left) repaired and (right) resected.

*Reprinted from the Journal of Biomechanics 43(5), Greaves et al, Effect of Acetabular Labral Tears, Repair and Resection on Hip Cartilage Strain: A 7T MR Study, pp858-863, 2010 with permission from Elsevier.*

## Conclusion

These *ex vivo* findings suggest labral resection increases cartilage compression compared to labral repair. Therefore, repairing the labrum may protect the hip from chondral damage. However, the type of tear must be considered when choosing repair or resection because not all labral tears have the capacity to heal<sup>[11]</sup>.

Further, when the torn labrum was repaired, mean cartilage compression was significantly decreased possibly due to the circumferentially stiffer repaired labrum. This finding indicates that repairing a torn labrum may protect the health of the cartilage in the hip.

## References

- (1) Byrd, J.W.T. Labral lesions: an elusive source of hip pain case reports and literature review. *Arthroscopy* 12[5], 603-612. 1996.
- (2) Hase T, Ueo T. Acetabular labral tear: arthroscopic diagnosis and treatment. *Journal of Arthroscopic and Related Surgery* 1999; 15(2):138-141.
- (3) Kelly BT, Williams RJ, Philippon MJ. Hip Arthroscopy: Current Indications, Treatment Options, and Management Issues. *The American Journal of Sports Medicine* 31[6], 1020-1037. 2003.
- (4) Espinosa N, Rothenfluh DA, Beck M, Ganz R, Leunig M. Treatment of femoro-acetabular impingement: Preliminary results of labral resection. *Journal of Bone and Joint Surgery* 2006; 88-A(5):925-935.
- (5) Larson CM, Giveans MR. Arthroscopic debridement versus resection of the acetabular labrum associated with femoroacetabular impingement. *Arthroscopy* 2009; 25(4):369-376.
- (6) Philippon MJ, Briggs KK, Yen YM, Kuppersmith DA. Outcomes following hip arthroscopy for femoroacetabular impingement with associated chondrolabral dysfunction: minimum two-year follow-up. *J Bone Joint Surg Br* 2009; 91(1):16-23.
- (7) Bullough P, Goodfellow J, O'Connor J. The relationship between degenerative changes and load-bearing in the human hip. *Journal of Bone and Joint Surgery* 1973; 55B(4):746-758.
- (8) Tan V, Seldes RM, Katz MA, Freedhand AM, Klimkiewicz JJ, Fitzgerald RH, Jr. Contribution of acetabular labrum to articulating surface area and femoral head coverage in adult hip joints: an anatomic study in cadavera. *Am J Orthop* (Belle Mead NJ) 2001; 30(11):809-812.
- (9) Greaves LL, Gilbert MK, Yung AC, Kozlowski P, Wilson DR. Effect of acetabular labral tears, repair and resection on hip cartilage strain: A 7T MR study. *J Biomech* 2010; 43(5):858-863.
- (10) Bergmann G, Deuretzbacher M, Heller M, Graichen F, Rohlmann A, Strauss J et al. Hip contact forces and gait patterns from routine activities. *Journal of Biomechanics* 2001; 34:859-871.
- (11) Kelly BT, Shapiro GS, Digiovanni CW, Buly RL, Potter HG, Hannafin JA. Vascularity of the hip labrum: a cadaveric investigation. *Arthroscopy* 2005; 21(1):3-11.

Courtesy of Smith & Nephew, Inc., Endoscopy Division

®Trademarks of Smith & Nephew, registered U.S. Patent & Trademark Office.



**Endoscopy**  
Smith & Nephew, Inc.  
Andover, MA 01810  
USA

**www.smith-nephew.com**  
+1 978 749 1000  
+1 978 749 1108 Fax  
+1 800 343 5717 U.S. Customer Service

©2010 Smith & Nephew, Inc.  
All rights reserved.

06/2010 10600699 Rev. A