

Knee Technique Guide

Modified Lemaire tenodesis with an iliotibial band graft and BIOSURE[◇] REGENESORB interference screw fixation

By Dr Eivind Inderhaug, M.D., MPH, PhD, based on collaboration with Mr Andy Williams MB BS FRCS (Ortho) FFSEM (UK) and Prof Andrew Amis PhD, DSc (Eng) FiMechE

Knee

Hip

Shoulder

Extremities

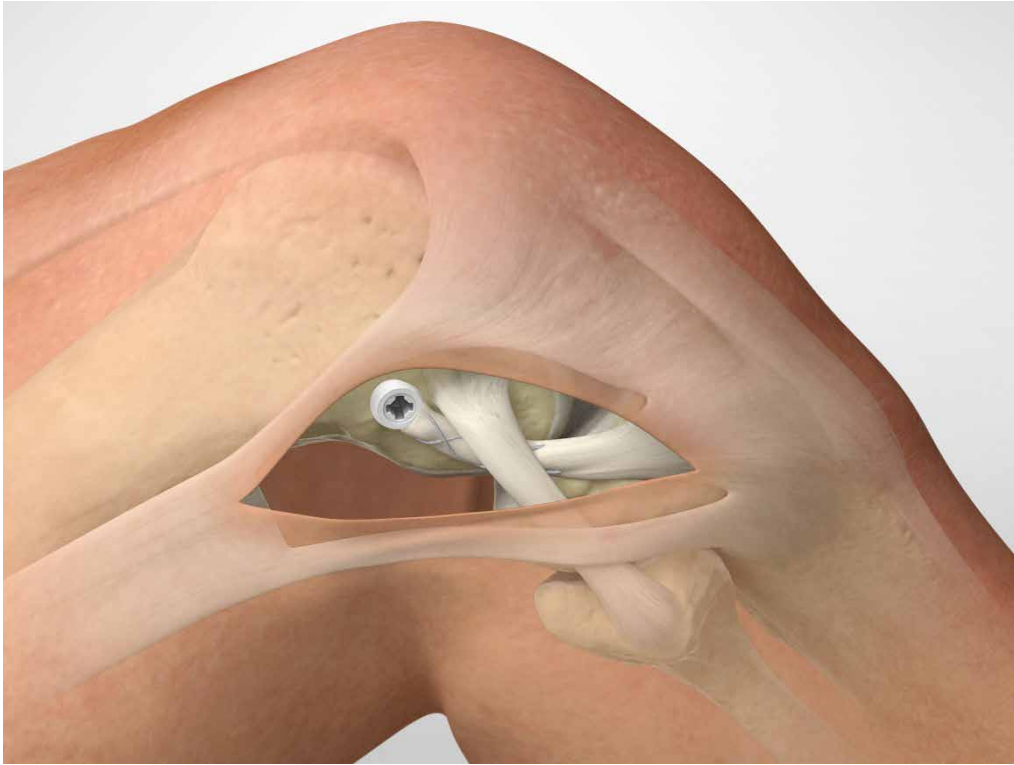
Modified Lemaire tenodesis with an iliotibial band graft and BIOSURE[◇] REGENESORB interference screw fixation

Table of Contents

Scope	5
Introduction	5
Patient Preparation	7
Surgical Technique	8
1. Expose the iliotibial band	8
2. Iliotibial band graft harvesting	9
3. Preparation of the femoral attachment	10
4. Graft passage	11
5. Positioning the graft	12
6. Suturing	13
Ordering Information	14
References	15

This surgical technique was prepared under the guidance of Dr. Eivind Inderhaug. Created under close collaboration with the physician, it contains a summary of surgical techniques and opinions based upon his training and expertise in the field, along with his knowledge of Smith & Nephew's BIOSURE REGENESORB interference screw.

Smith & Nephew does not provide medical advice and recommends that surgeons exercise their own professional judgement when determining a patient's course of treatment. Smith & Nephew does not recommend any particular product or surgical technique for a specific patient. This surgical technique is presented for educational purposes only. For more information on the products in this surgical technique, including indications for use, contraindications, effects, precautions and warnings, please consult the products' Instructions for Use (IFU).



For illustrative purposes only. Results may vary.

Scope / Introduction

Scope

The aim of the modified Lemaire anterolateral tenodesis is to improve anterolateral rotational stability, either as a supplement to an anterior cruciate ligament (ACL) reconstruction in a knee with a high degree of rotational instability, or as an addition during ACL revision surgery.

The technique herein described is a modified Lemaire procedure, using a less invasive approach, with a transposed iliotibial band graft fixed by a BIOSURE® REGENESORB interference screw.

Introduction

Anterolateral procedures were traditionally used as the sole procedure for ACL insufficiency. Although efficient in reducing rotational instability at the time of surgery, clinical results at the time were variable¹. With the introduction of the intra-articular ACL reconstruction, the popularity of these procedures declined. However, the extra-articular procedures in combination with intra-articular ACL reconstruction were still being used, and several clinical studies have shown improved knee stability and better patient-reported outcomes when the combined approach is used²⁻⁵, as opposed to an intra-articular ACL reconstruction alone.

A rationale for the additional effect of anterolateral procedures can be found in studies that investigate the role of anterolateral structures of the knee^{1, 6, 7}. While a common perception has been that the ACL is paramount for rotational control of the knee (additional to its role in controlling anterior translation of the knee), recent biomechanical studies have shown that the anterolateral structures are in fact the primary stabilisers of internal rotation⁷. Concurrently, clinical findings – at both the time of surgery and during radiological examinations – indicate that these anterolateral structures are commonly injured when an ACL tear is present⁸⁻¹⁰. In sum, evidence is building up to support the fact that injuries to anterolateral structures of the knee are a non-negligible factor of the anterolateral rotational instability (ALRI) or pivot shift – the hallmark clinical sign that is seen in an ACL insufficient knee. It has been shown in a recent biomechanical study, that when performing only an intra-articular ACL reconstruction in a knee presenting with combined ACL and anterolateral injuries, residual laxity for both anterior translation and internal rotation of the knee remained⁶. When a modified Lemaire anterolateral tenodesis was added, normal knee laxity was, however, restored⁶.

Prepared in Consultation with:

Dr Eivind Inderhaug,
Consultant Knee Surgeon,
Surgical Clinic
Haralds plass Deaconess Hospital
Pbox 6165
5892 Bergen
Norway

A long-standing fear with the anterolateral tenodesis has been the perceived risk of lateral compartment osteoarthritis associated with such procedures¹¹. A suggested mechanism for the development of lateral compartment osteoarthritis is over constraint of the lateral compartment, leading to an increase in tibiofemoral cartilage contact pressures. Although there is no clear evidence that supports such a link, this has been a prevailing opinion amongst knee surgeons. In a cadaveric study investigating the effect of graft tensioning protocols on intra-articular tibiofemoral contact pressures, a low risk of increased intra-articular contact pressures was observed¹². The key factors for keeping intra-articular pressures normal included: (1) keeping the knee in a neutral rotation, and (2) using only a moderate graft tension (2 kg) when fixating the anterolateral graft. These findings highlight important technical factors to be considered in the anterolateral procedures. Renewed clinical follow-up evaluations will hopefully reproduce the normalised knee kinematics found in these time-zero cadaveric studies.

The modified Lemaire tenodesis is an procedure that is indicated as a supplement to anterior cruciate ligament (ACL) reconstruction in selected cases. Although the best use of the procedure is still under development, current indications have been suggested to be primary ACL cases with a large rotational instability (clinically assessed by the pivot shift manoeuvre), patients with a high risk of failure after surgery and selected revision cases. There are also indications that a combined intra-articular ACL reconstruction and an extra-articular procedure can have a protective effect on the ACL graft during early postoperative rehabilitation¹³.

The current technique is a modification of the eponymous procedure described by Marcel Lemaire in 1967¹⁴. It has been used conventionally since then, but modifications have led to the current, less invasive, approach. With the use of a transposed graft from the iliotibial band, there is only need for a single incision with no additional tendon harvesting required.

The current technique tunnels the graft deep to the lateral collateral ligament, which restores reliable knee kinematics and normalises the rotational instability of the knee. It is easy to perform with the bony landmarks for graft insertion being identifiable through the open approach used. By using only one fixation device at the femoral insertion, there is a reduced risk of graft slippage as well as reduced costs related to the procedure. The BIOSURE® REGENESORB Interference Screw provides reliable fixation for the femoral insertion site with a unique open architecture design that allows for bone in-growth¹⁵.

Patient Preparation

Patient Preparation

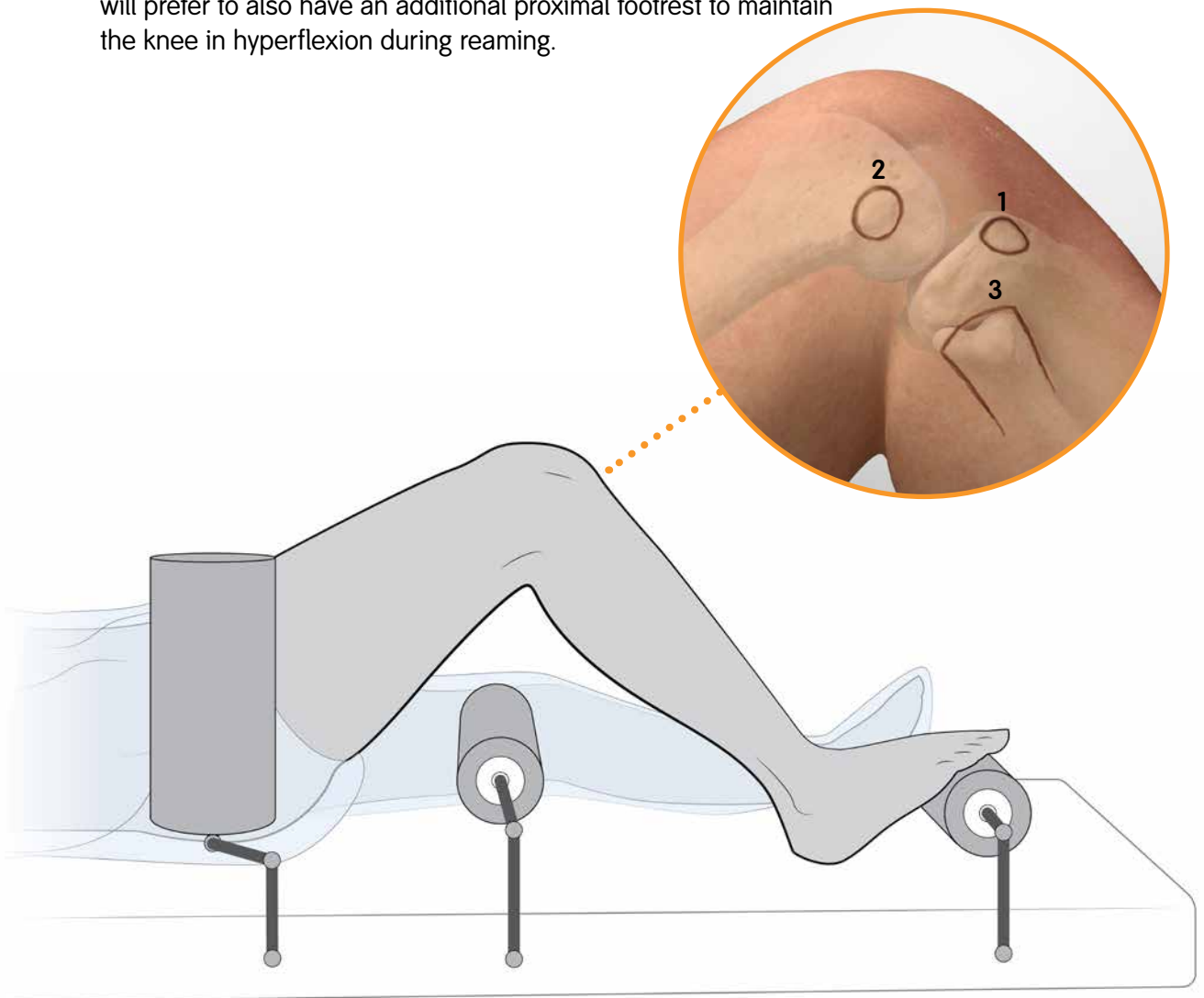
The procedure is performed with knee flexion starting at 90 degrees. The patient should be positioned as for an ACL reconstruction, lying supine on an operating room table. A lateral hip pad is used to stabilise the pelvis and support the thigh. A distal foot rest is adjusted so that the knee is maintained in 90° of flexion.

The lateral landmarks should be palpated and marked on the skin with a surgical marker pen.

1. Gerdy's tubercle
2. Lateral epicondyle
3. Fibular head

Note:

For an ACL reconstruction where the femoral tunnel is reamed via an accessory anteromedial arthroscopic portal, some surgeons will prefer to also have an additional proximal footrest to maintain the knee in hyperflexion during reaming.



Surgical Technique

The surgical technique is composed of 6 surgical steps.

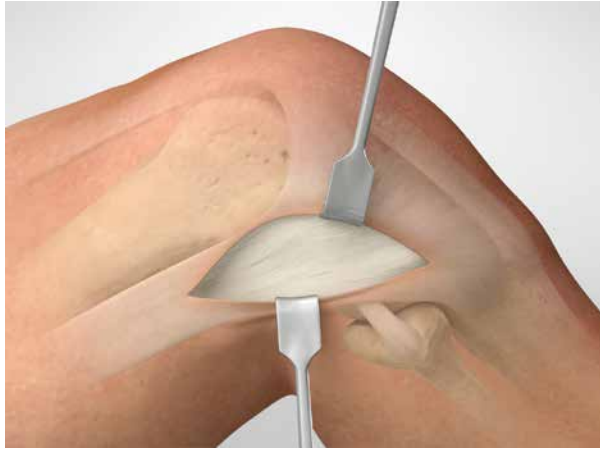

Figure 1

1. Expose the iliotibial band

- a. Make an oblique skin incision from Gerdy's tubercle to the lateral epicondyle.
- b. Using a scalpel, carefully dissect the soft tissue down to expose the iliotibial band (Fig 1).

Tip:

If the knee is positioned in a figure-of-four position, the lateral collateral ligament (LCL) can also be found in its extent from the fibular head to the lateral epicondyle.

Surgical Technique

2. Iliotibial band graft harvesting

- a. Demarcate and harvest an 8 cm long and 1.5 cm wide strip from the middle part of the iliotibial band (**Fig 2**).
- b. Leave the distal end attached to Gerdy's tubercle and detach the proximal end with a scalpel.

Important:

Use careful dissection when releasing the proximal end of the graft, as the lateral genicular artery is sometimes found in this area. A lesion to the lateral genicular artery may cause bleeding and postoperative hematoma.

- c. The free end of the graft is whipstitched with high strength #2 ULTRABRAID[®] suture (**Fig 3**).

Important:

Take care, not to injure the lateral collateral ligament when harvesting the iliotibial band graft.

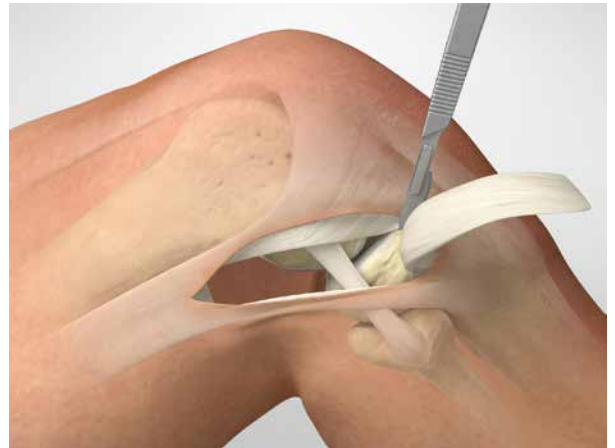

Figure 2

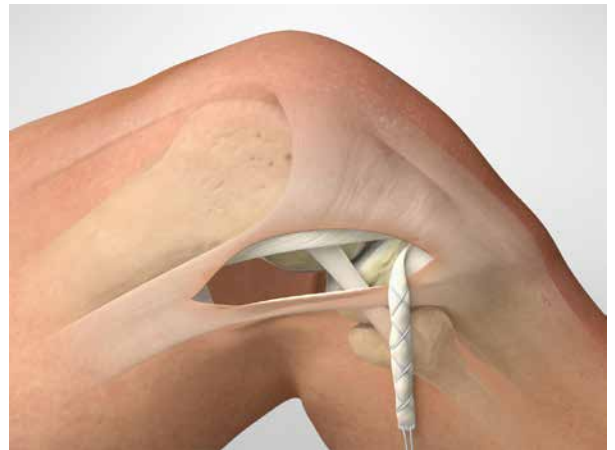

Figure 3



ULTRABRAID #2
suture and needle
assembly, white
Cat. No. 7210914

Surgical Technique

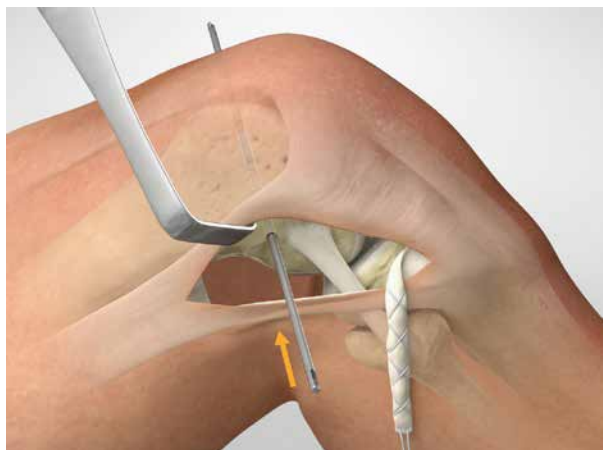

Figure 4

3. Preparation of the femoral attachment

- a. Identify the lateral collateral ligament.
- b. Locate the femoral insertion of the graft at just proximal and posterior to the lateral epicondyle¹⁶.

Note:

It is important to identify the correct femoral graft insertion site to maintain ideal graft tensioning properties.

- c. Carefully remove the soft tissue overlying the femoral insertion site using cautery.
- d. Position a 2.4 mm eyelet Kirschner-wire (K-wire) at the insertion site.
- e. Drill the 2.4 mm K-wire through the lateral cortex out of the medial femoral cortex in a slightly anterior and proximal direction to avoid conflict with the ACL femoral tunnel (**Fig 4**).
- f. Over-ream the guide pin with an 8 mm cannulated headed reamer to a depth of 20 mm (**Fig 5**).

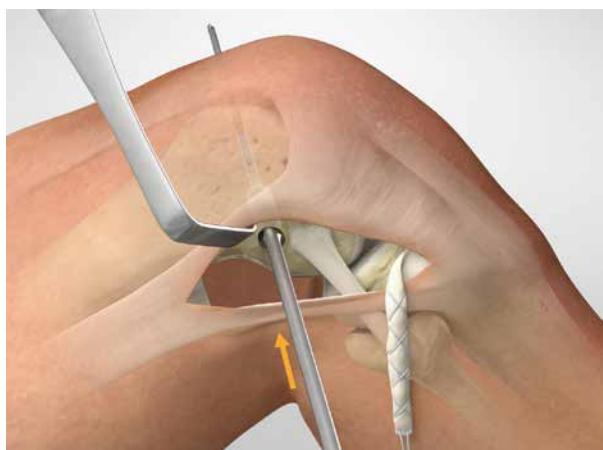

Figure 5



ACUFEX[®]
Endoscopic Drill
8 mm
Cat. No. 013661



2.4 mm x 15"
Drill-Tip Passing
Pin
Cat. No. 72202817

Surgical Technique

4. Graft passage

- a. Using scissors, carefully separate the layer between the lateral collateral ligament and the lateral capsule, from distal to proximal, whilst preserving the joint capsule (**Fig 6**).
- b. Use a curved clip to route the passing suture of the iliotibial band graft, followed by the iliotibial band graft, from distal to proximal, deep to the lateral collateral ligament (**Fig 7**).

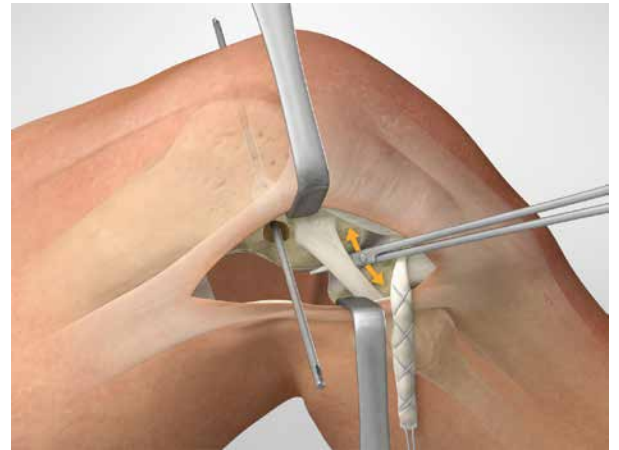


Figure 6

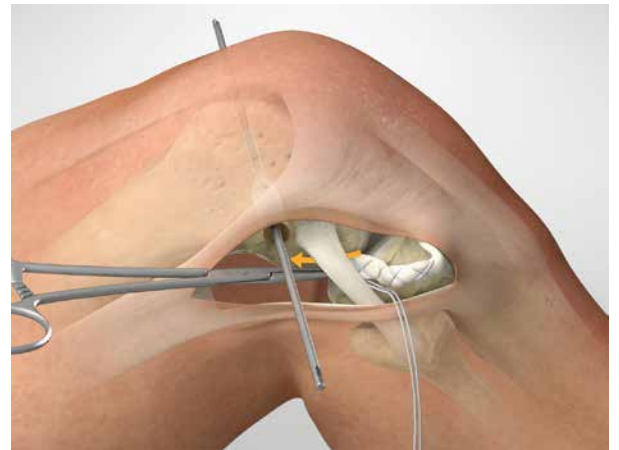

Figure 7

Surgical Technique

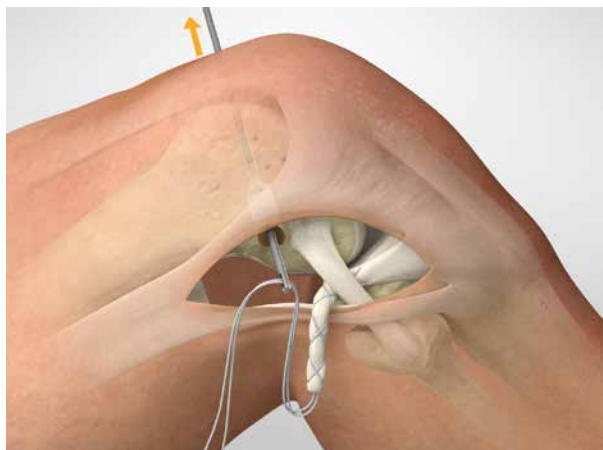


Figure 8

5. Positioning the graft

- Thread the passing suture through the eyelet of the 2.4 mm K-wire.
- Pull the 2.4 mm K-wire out of the contralateral cortex, pulling the iliotibial band graft into the femoral tunnel (**Fig 8, 9**).
- Place a nitinol wire in the femoral tunnel to facilitate later interference screw fixation.
- Manually set the correct graft tension by pulling the graft (only 20 N [2 kg] if needed)^{10, 12}.
- Position the knee at 30° of flexion with neutral rotation in the leg¹⁷ and fix the graft into the femoral tunnel with an 8 mm x 20 mm or 9 mm x 20 mm BIOSURE® REGENESORB Interference Screw according to bone hardness (**Fig 10**).

Important:

No more than 20 N (2 kg) pull should be used at the time of fixation^{10, 12}.

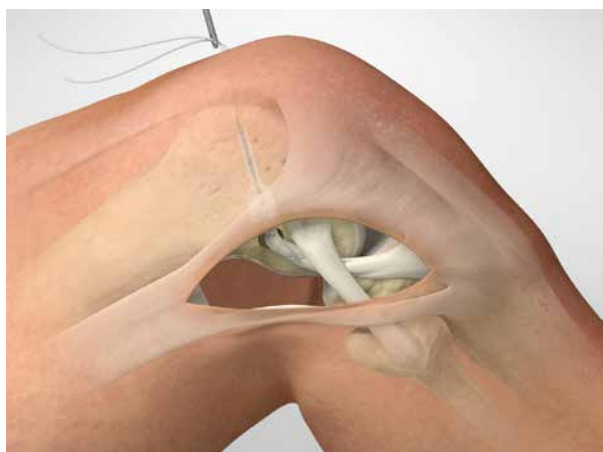

Figure 9

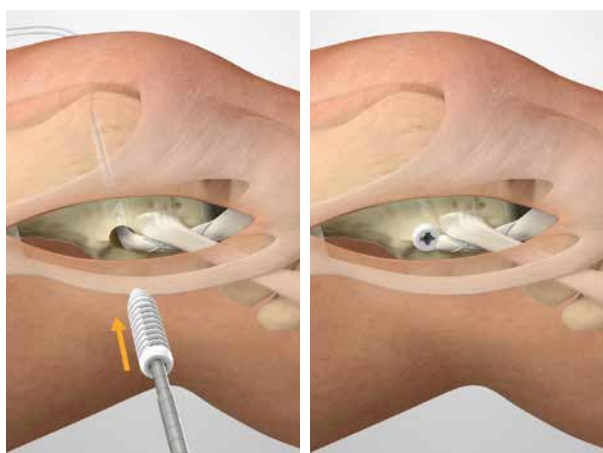


Figure 10



Nitinol Wire
Cat. No. 7211137

BIOSURE
REGENESORB
9 mm x 20 mm
Cat. No. 72204403
8 mm x 20 mm
Cat. No. 72204398

Surgical Technique

6. Suturing

- a. Close the iliotibial band using absorbable VICRYL® sutures at the proximal end to avoid potential muscular herniation (Fig 11).
- b. Close subcutaneous tissue using absorbable VICRYL®.
- c. Use intracutaneous MONOCRYL® sutures for skin closure.

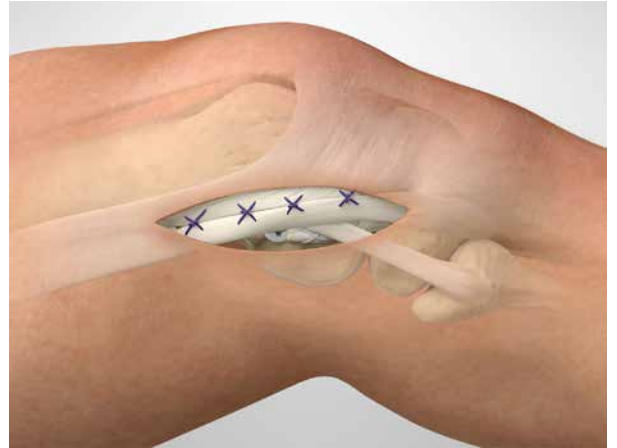

Figure 11

Ordering Information

Ordering Information

To order the instruments used in this technique contact an authorised Smith & Nephew representative. Prior to performing this technique, consult the Instructions for Use documentation provided with individual components – including indications, contraindications, warnings, cautions and instructions.

ACUFEX® Director Elite Drill Guide System

Reference #	Description
-------------	-------------

013661	Endoscopic Drill 8 mm
--------	-----------------------

BIOSURE® REGENESORB Interference Screw

Reference #	Description
-------------	-------------

72204398	BIOSURE REGENESORB Interference Screw, 8 mm x 20 mm
----------	---

72204403	BIOSURE REGENESORB Interference Screw, 9 mm x 20 mm
----------	---

Instruments

Reference #	Description
-------------	-------------

7211138	Guide Wire, 1.2 mm x 12" sterile (5 per box)
---------	--

72201201	Guide Wire, 1.2 mm x 18" sterile (5 per box)
----------	--

72201887	BIOSURE Driver
----------	----------------

72201888	BIOSURE Ratchet Driver (requires Ratcheting Handle with Hudson Adapter 7207707)
----------	---

7207707	Ratcheting Handle with Hudson Adapter
---------	---------------------------------------

72202817	2.4 mm x 15" Drill-Tip Passing Pin, sterile, single use (6 per package)
----------	---

Sutures

Reference #	Description
-------------	-------------

7210914	ULTRABRAID #2 suture and needle assembly, 38", white, single package, sterile (10 per box)
---------	--

7210915	ULTRABRAID #2 COBRAID® suture and needle assembly, 38", COBRAID-blue, single package, sterile (10 per box)
---------	--

Indications for use

The BIOSURE REGENESORB Interference Screw is indicated for the reattachment of ligament, tendon, soft tissue, or bone-tendon-bone grafts.

References

References

1. Dodds AL, Gupte CM, Neyret P, Williams AM, Amis AA. Extra-articular techniques in anterior cruciate ligament reconstruction: a literature review. *J Bone Joint Surg Br.* 2011;93(11):1440-8.
2. Marcacci M, Zaffagnini S, Iacono F, Vascellari A, Loreti I, Kon E, et al. Intra- and extra-articular anterior cruciate ligament reconstruction utilizing autogeneous semitendinosus and gracilis tendons: 5-year clinical results. *Knee Surg Traumatol Arthrosc.* 2003;11(1):2-8.
3. Noyes FR, Barber SD. The effect of an extra-articular procedure on allograft reconstructions for chronic ruptures of the anterior cruciate ligament. *J Bone Joint Surg Am.* 1991;73(6):882-92.
4. Vadala AP, Iorio R, De Carli A, Bonifazi A, Iorio C, Gatti A, et al. An extra-articular procedure improves the clinical outcome in anterior cruciate ligament reconstruction with hamstrings in female athletes. *Int Orthop.* 2013;37(2):187-92.
5. Zaffagnini S, Marcacci M, Lo Presti M, Giordano G, Iacono F, Neri MP. Prospective and randomized evaluation of ACL reconstruction with three techniques: a clinical and radiographic evaluation at 5 years follow-up. *Am J Sports Med.* 2006;14(11):1060-9.
6. Kittl C, El-Daou H, Athwal KK, Gupte CM, Weiler A, Williams A, et al. The Role of the Anterolateral Structures and the ACL in Controlling Laxity of the Intact and ACL-Deficient Knee. *Am J Sports Med.* 2016;44(2):345-54.
7. Goldman AB, Pavlov H, Rubenstein D. The Segond fracture of the proximal tibia: a small avulsion that reflects major ligamentous damage. *Am J Roentgenol.* 1988;151(6):1163-7.
8. Mansour R, Yoong P, McKean D, Teh JL. The iliotibial band in acute knee trauma: patterns of injury on MR imaging. *Skeletal Rad.* 2014;43(10):1369-75.
9. Terry GC, Norwood LA, Hughston JC, Caldwell KM. How iliotibial tract injuries of the knee combine with acute anterior cruciate ligament tears to influence abnormal anterior tibial displacement. *Am J Sports Med.* 1993;21(1):55-60.
10. Inderhaug E, Stephen JM, Williams A, Amis AA. Biomechanical comparison of anterolateral procedures combined with ACL reconstruction. *Am J Sports Med.* 2016. DOI:10.1177/0363546516681555.
11. Ferretti A. Extra-articular reconstruction in the anterior cruciate ligament deficient knee: a commentary. *Joints.* 2014;2(1):41-7.
12. Inderhaug E, Stephen JM, Williams A, Amis AA. The effect of anterolateral tenodesis on tibiofemoral contact pressure and kinematics. *Am J Sports Med.* 2016 Accepted.
13. Engebretsen L, Lew WD, Lewis JL, Hunter RE. The effect of an iliotibial tenodesis on intraarticular graft forces and knee joint motion. *Am J Sports Med.* 1990;18(2):169-76.
14. Lemaire M. Ruptures anciennes du ligament croisé antérieur du genou. *J Chirurg.* 1967;93:311-20.
15. Data on file at Smith & Nephew, reports 15004843, 15002832, 15002353, 15002699.
16. Kittl C, Halewood C, Stephen JM, Gupte CM, Weiler A, Williams A, et al. Length change patterns in the lateral extra-articular structures of the knee and related reconstructions. *Am J Sports Med.* 2015;43(2):354-62.
17. Inderhaug E, Stephen JM, Williams A, Amis AA. Anterolateral tenodesis or ALL reconstruction: effect of flexion angle at graft fixation when combined with ACL reconstruction. 2016 Under review.



Manufactured by:
Smith & Nephew, Inc.
150 Minuteman Road
Andover, MA 01810
USA

www.smith-nephew.com

©2017 Smith & Nephew, Inc.
All rights reserved.
Trademark of Smith & Nephew. Reg. US Pat.
& TM Off. All Trademarks acknowledged.

