

REGENETEN[®] Bioinductive Implant promotes rapid and sustained healing of partial-thickness (PT) rotator cuff tears

Tear healing is linked to significant improvement in function and reduction in pain compared to preoperative values over 24 months



Study overview

- A prospective study of 13 patients (mean age, 53.8 years) with various grades and locations of PT tears of the supraspinatus tendon
- All patients received a REGENETEN Bioinductive Implant over the bursal surface of the tendon following arthroscopic subacromial decompression without repair
- MRI and clinical outcome assessments were conducted preoperatively and at 3, 6, 12 and 24 months postoperatively



Key results

- Significant mean increase in tendon thickness of 2.2mm at 3 months versus preoperative values ($p < 0.0001$)
- At 12 months, new tissue was indistinguishable from underlying tissue in 12/13 patients (92%)
- Tendon thickness at 24 months was significantly thicker ($p < 0.0001$) than preoperative values
- At 12 months, all assessable patients had a reduction in tear size of ≥ 1 grade, with complete tear disappearance in 7 of 10 patients with measurable tear size (70%) (Figure)
- Significant improvement in clinical scores throughout 24-month follow-up period
 - Constant-Murley score ($p \leq 0.01$) and Constant-Murley pain score ($p \leq 0.001$)
 - American Shoulder and Elbow Surgeons (ASES) total score and ASES pain score (both $p \leq 0.001$)
- Outcomes were satisfactory for 12/13 patients (92%) at 24 months, suggesting a benefit over acromioplasty alone

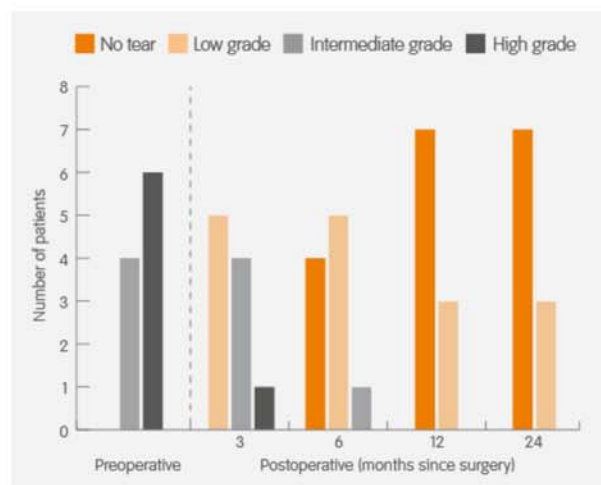


Figure. Sequential improvement and healing of cuff defects over 24 months (n=10)



Conclusion

When treated with REGENETEN Bioinductive Implant, partial-thickness rotator cuff tears can decrease in size and in most cases completely heal. Tear healing is associated with the formation of load-bearing, tendon-like tissue, ultimately leading to improved clinical outcomes.



Study citation

*Bokor DJ, Sonnabend D, Deady L, et al. Evidence of healing of partial-thickness rotator cuff tears following arthroscopic augmentation with a collagen implant: a 2-year MRI follow-up. *Muscles Ligaments Tendons J*. 2016;6(1):16-25.

Available at: Muscle, Ligaments and Tendons Journal